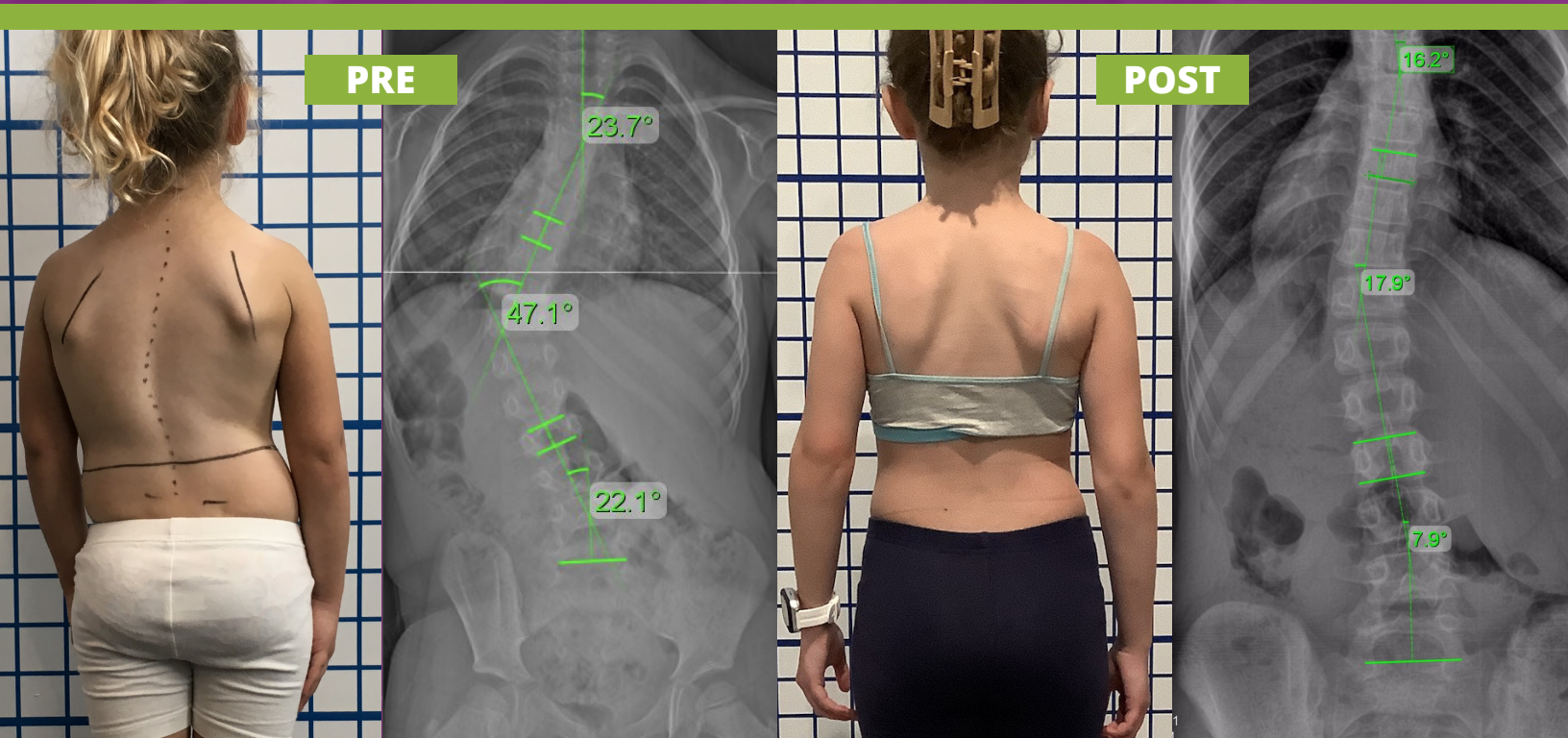

# Scoliosis Reduction Center<sup>®</sup> Case Study

Name: Amelia O  
Type: Idiopathic  
Age: Juvenile (2-10)  
Severity: Severe (40/45 ° - 80°)

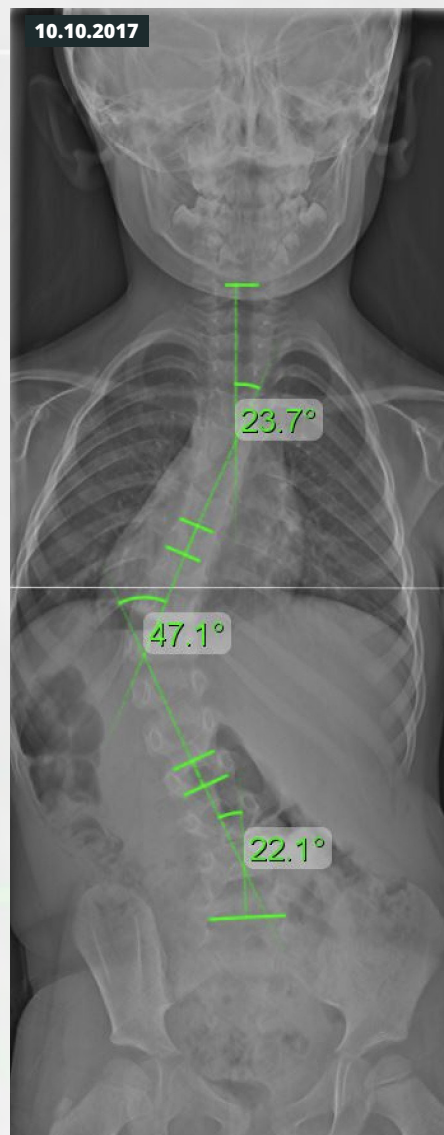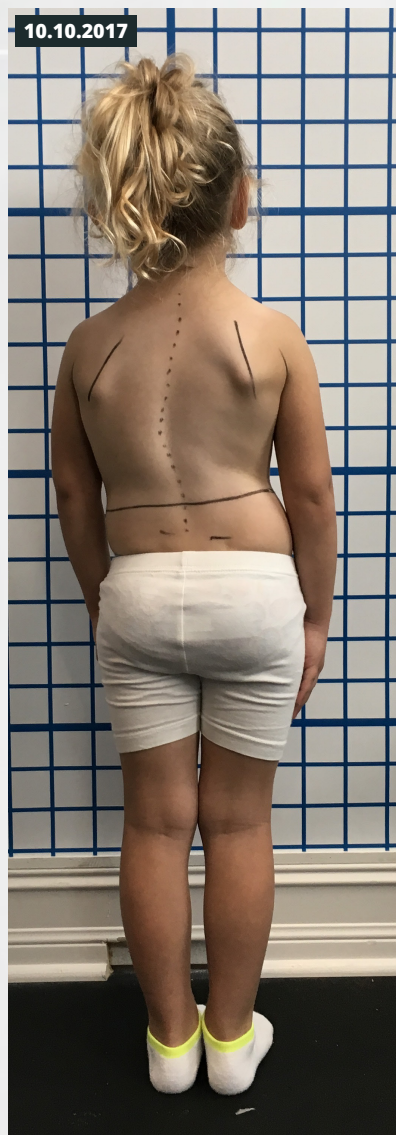BY DR. TONY NALDA

# Initial Evaluation:

During Amelia's initial assessment, her scoliosis was measured at 47.1 degrees, placing it within the severe range. At the time of evaluation, Amelia reported no discomforts and being a very active child. This evaluation was conducted through a thorough and comprehensive process.

## Before Meeting Dr Tony:

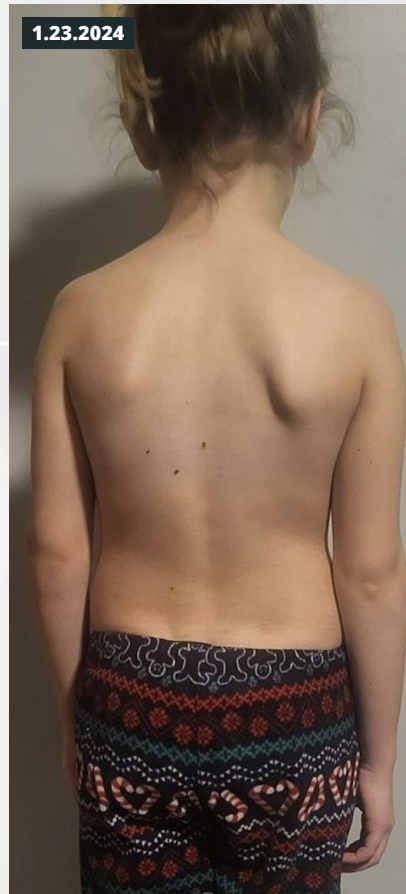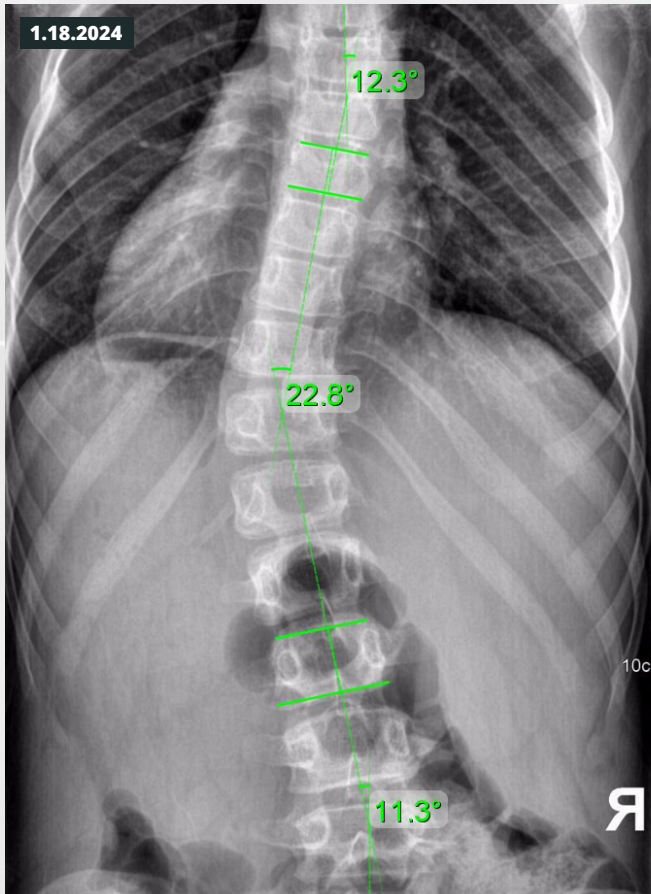
Amelia was diagnosed with scoliosis at roughly 18 months of age. Amelia underwent exercises to strengthen her spine and chiropractic treatment prior to being referred to Dr. Tony Nalda at 4 years old.



# Mid-Treatment

## Challenging Aspects of this Particular Case:

Living several states from the clinic and Amelia's age added complexity to her treatment.



## Treatment Modalities Used:

- ◆ **Standing Vibrating Traction** - Used to elongate the spine while standing on vibration. the vibration helps to amplify anything we do while on the traction. We can customize this traction using weights and exercises to target specific areas of the spine from the cervical to the lumbar.
- ◆ **Vibrating Traction** - Low tone vibration traction used to relax ligaments of the spine.
- ◆ **Flexion Distraction** - provides traction to the lumbar spine, by added the straps we are able to create counter rotations and unbend the specific areas of the scoliosis.
- ◆ **Scoliosis Traction Chair** - targeted traction and derotation focusing on the thoracic and lumbar areas not possible with other types of traction while promoting relaxation and potential curve reduction.

## Re-evaluation Checkpoints:

90 days post Amelia's initial treatment, her family provided the requested details to continue monitoring her care remotely including x-rays, posture pictures, and a descriptive update on her post-treatment progress. Amelia's assessment revealed maintained reduction and improved posture. However, due to a growth spurt, Amelia was recommended to continue with another 5-day treatment and a new brace.

With the goal of further reducing Amelia's curvature, her family choose to continue with another treatment and new brace. This approach led to a continued reduction in her curvature and now being classified as mild scoliosis.

Amelia adhered to her prescribed home therapy and wore her Scolibrace. Another remote evaluation was provided 90 days later, revealing slight progression potentially due to growth. As a result, modifications to her brace were suggested. Following these adjustments, Amelia experienced further reduction and stabilization of her scoliosis.

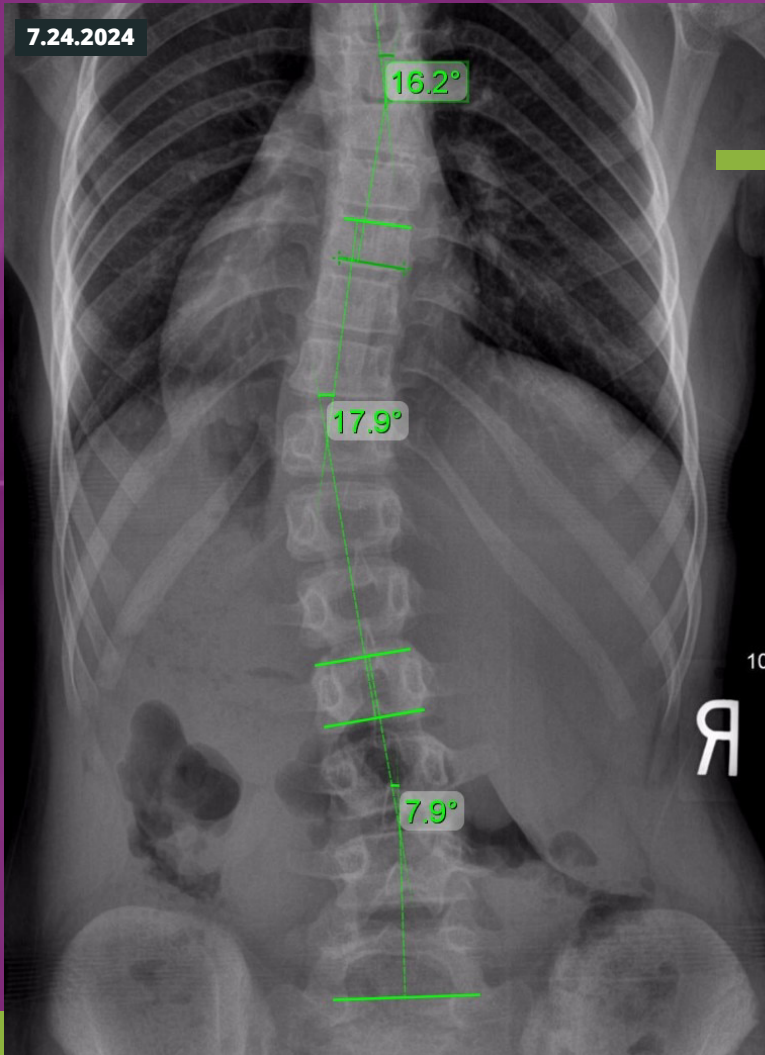
With careful monitoring and home posture pictures, Amelia successfully stabilized her curvature. After 90 days, a remote evaluation indicated that she remained asymptomatic and stable. At this point, it was recommended that she transition to part-time bracing or consider a new symmetrical brace. Eager to continue reducing Amelia's curvature, her family decided on a new symmetrical brace and additional 5-day treatment, which resulted in further correction and classified her scoliosis as mild.

After several remote evaluations, Amelia was completely weaned from her brace. For a year, she maintained her stabilization until after a growth spurt prompted some progression. Recommendations included adding part-time bracing during puberty or ongoing monitoring. Following a cautious approach, her family opted to proceed with a new brace and treatment, successfully reducing Amelia's scoliosis once again.

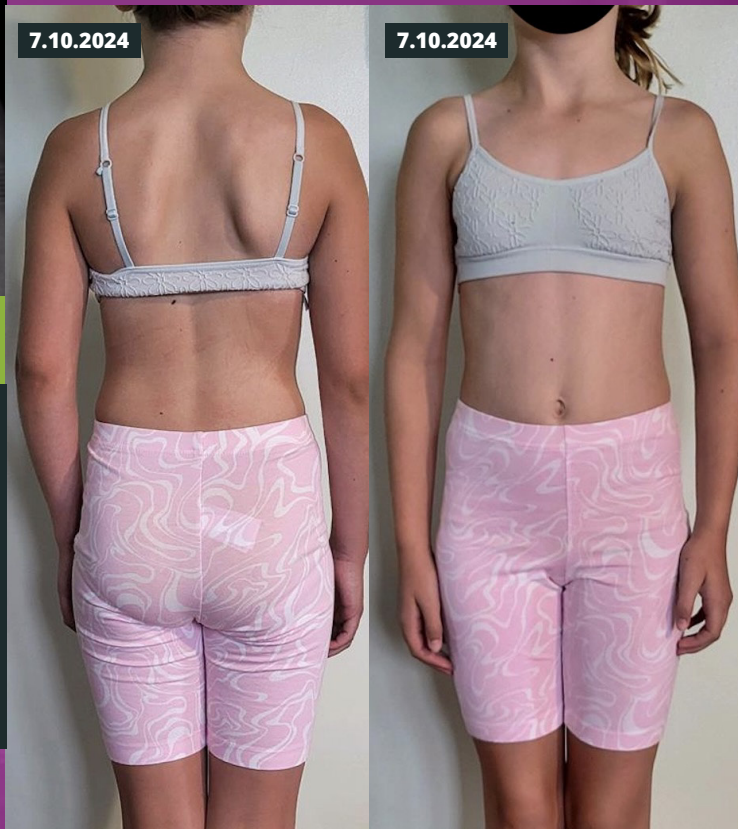90 days post treatment Amelia's family provided updated remote evaluation information showing a slight decreased in her curvature since her last treatment. Amelia continues with her prescribed home therapy and brace wearing, all while being closely being monitored throughout her development.



# Long-Term Results:



Amelia has achieved fantastic long-term improvement with her dedication to her prescribed treatment and wonderful home support system. With Amelia's initial scoliosis assessment showing 47.1 degrees to her current improved scoliosis showing 17.9 degrees, and notable posture improvements.



## Dr. Tony Notes/Nuances/Thoughts

This family embodies a strong commitment and determination to achieve the best possible outcome for their daughter—one that avoids surgery! Their dedication is truly admirable.